Uroradiology
For Medical Students

Lesson 7

Computerized Tomography – 1

American Urological Association

Objectives

- In this lesson you will learn
  - How computerized tomography (CT) is performed
  - How to read CT images
  - How contrast media can enhance CT scans
- Plus
  - You will learn about three conditions for which CT imaging is useful. We're not going to spoil the surprise by mentioning them here, but we expect you to know them by the time you complete this tutorial.

Introduction

- You’ve seen how ultrasound, cystography and nuclear renography allow us to see the urinary tract in unique ways. Ultrasound gives detailed images of the kidney, but tells us nothing about renal function. Nuclear renography accurately measures renal function and drainage, but the images are low resolution. CT gives us both detailed images and also an accurate representation of renal function.

Case History

- 47 year old female bank president presented to the ER with a history of 5 days of worsening intermittent sharp L flank pain and nausea with gross hematuria
  - Past history: recurrent urinary tract infections and kidney stones
- Exam- afebrile, BP = 116/76, P = 115
  - Abdomen: L flank pain on palpation but no guarding or rebound tenderness
  - Urinalysis: Many RBCs, 5-10 WBCs/hpf, - nitrites

Evaluation?

- Urinalysis shows some RBCs and WBCs, but no bacteria, and she is afebrile
- History of stones raises the possibility of recurrence
- She could have both infection and a stone. Can the two conditions be related? If she had an obstructing kidney stone with infection in the kidney, she'd be at high risk for sepsis.
- What imaging technique would help us sort this out?

- Ultrasound could detect hydronephrosis, but it is not very sensitive for small stones
- We could probably see a stone on KUB, but that wouldn’t tell us if she has obstruction
- Nuclear renal scan would detect obstruction, but it cannot detect stones

- CT gives us a unique view of renal anatomy and function that would be useful for this patient

CT Scan-The Physics

- Vastly simplified, CT scanners emit x-rays that pass through the body and are detected by a sensor . A computer records the amount of x-radiation that has passed through the body and both the rotational and vertical positions of the x-ray tube at each reading. Through complex mathematical analysis, a 2-dimensional representation is made of the body.

CT Scanner

- Tube emits x-rays
- Measured by sensor on opposite side of a circular frame

- Computer generated image represents x-ray transmission as a level of gray, from pure black to white

CT Images

- Like conventional x-rays, CT images reflect transmission of x-radiation through the body, so objects that absorb x-rays appear white on the scan. We call such objects radiodense.

- On an abdominal scan, what object is most radiodense?
  - Bone

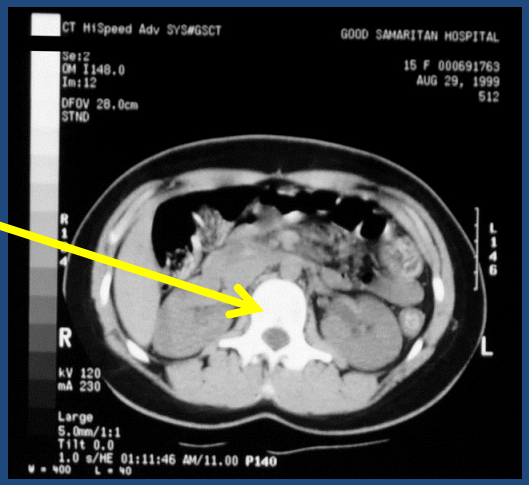

CT Images

- Objects that allow the x-rays to pass through appear black. These are referred to as radiolucent.

- What object on an abdominal scan is most radiolucent?
  - Air in the bowel

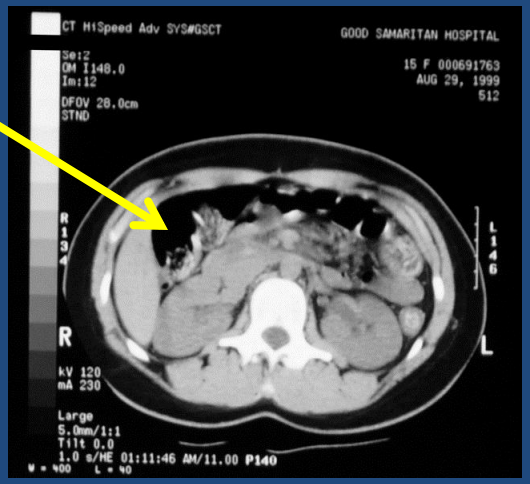

CT Gray-scale Reconstruction

- Through a mathematical calculation, the computer constructs a graphic image, assigning a number (called Hounsfield unit after Geoffrey Hounsfield, the British engineer who invented CT) to represent the radiodensity at each point. The number for each point in the image (pixel) is shown as a level of gray.
- The levels of gray (Hounsfield numbers) range from -1,000 (black) to 1,000 (white). Zero is the radiodensity of water.

CT Hounsfield Scale

Object	Hounsfield Unit
Air	-1,000
Fat	-100
Water	0
Kidney (No contrast)	30
Kidney stone	300
Bone	800

We'll see how Hounsfield units help us to identify objects we see on CT scans a little later.

CT Scan Basics

- It is difficult to see the full 1,000 to -1,000 spectrum on a computer monitor, so the CT technician chooses a range to view. This range of gray is called the **window**.
- Almost all CT imaging of the urinary tract is done using a chest/abdomen window.

CT Windows

Bone Window

Chest-Abdomen Window

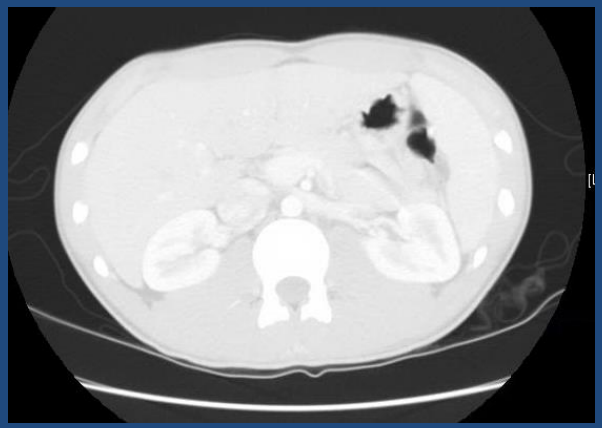

Lung Window

Note how the organs of the abdomen are easier to see on the chest-abdomen window. When you look at CT images you may have to change the window to see the structures you want to examine.

CT Scan Planes

- Once the scanning is complete, the computer can construct images that show the body from different perspectives.

Transverse / Axial

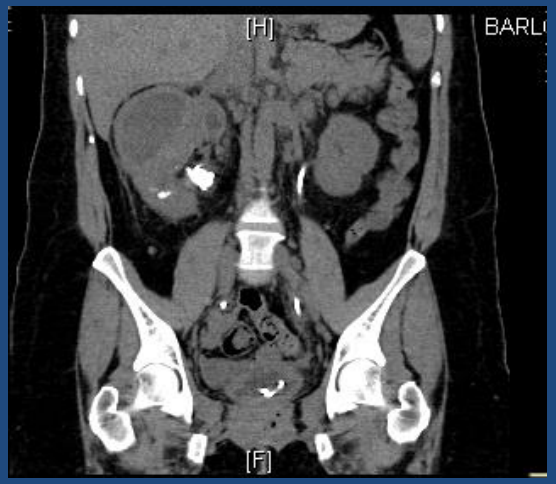

Coronal

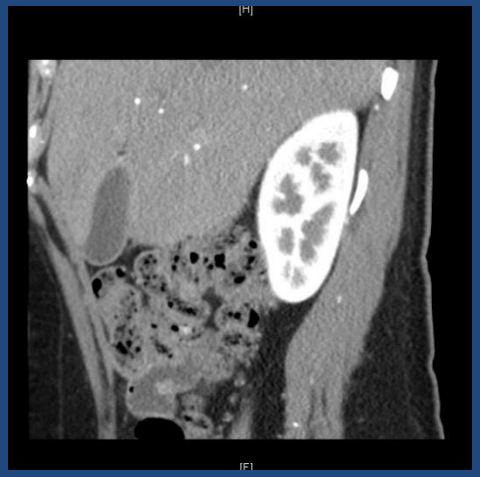

Sagittal

CT Images

- The most common visual perspective used in CT scans is a transverse or axial image.
- On transverse images, the right side of the body appears on the left side of the image as if you were looking up at the body from the feet.

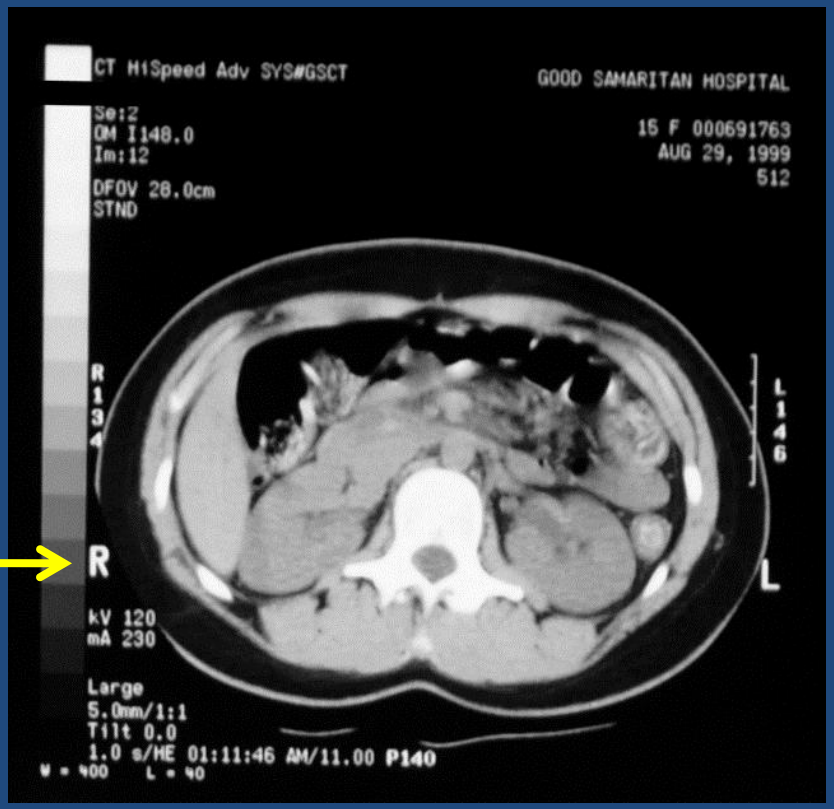

CT Images

- There are a few other things you should notice on the image labeling. You can determine the vertical position the cut (slice) represents by looking for two labels:
  - image number

    and
  - thickness.

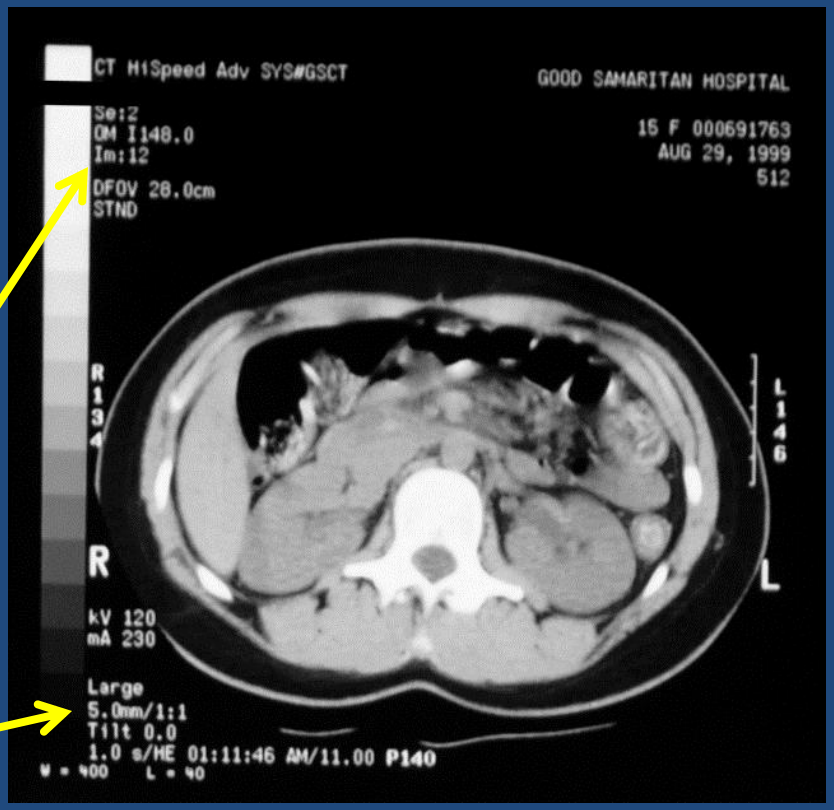

CT Measurement

- Thickness means just that, how thick each cut is. CT scans are usually performed from cephalad to caudad. An abdominal scan series is usually referenced to the zyphoid. So image # 12 on a CT with 5 mm cuts would be:

  12 x 5 mm or 60 mm caudad to the xyphoid

Our patient's laboratory tests are back

- WBC: 9,000 — If she had a serious infection, we'd expect a higher WBC

- BUN: 21 mg/dl — Normal kidney function
- Creatinine: 1.0 mg/dl

- Management:
  - Antibiotics as a precaution pending urine culture
  - Hydration
  - Analgesics

Let's look at our patient's CT

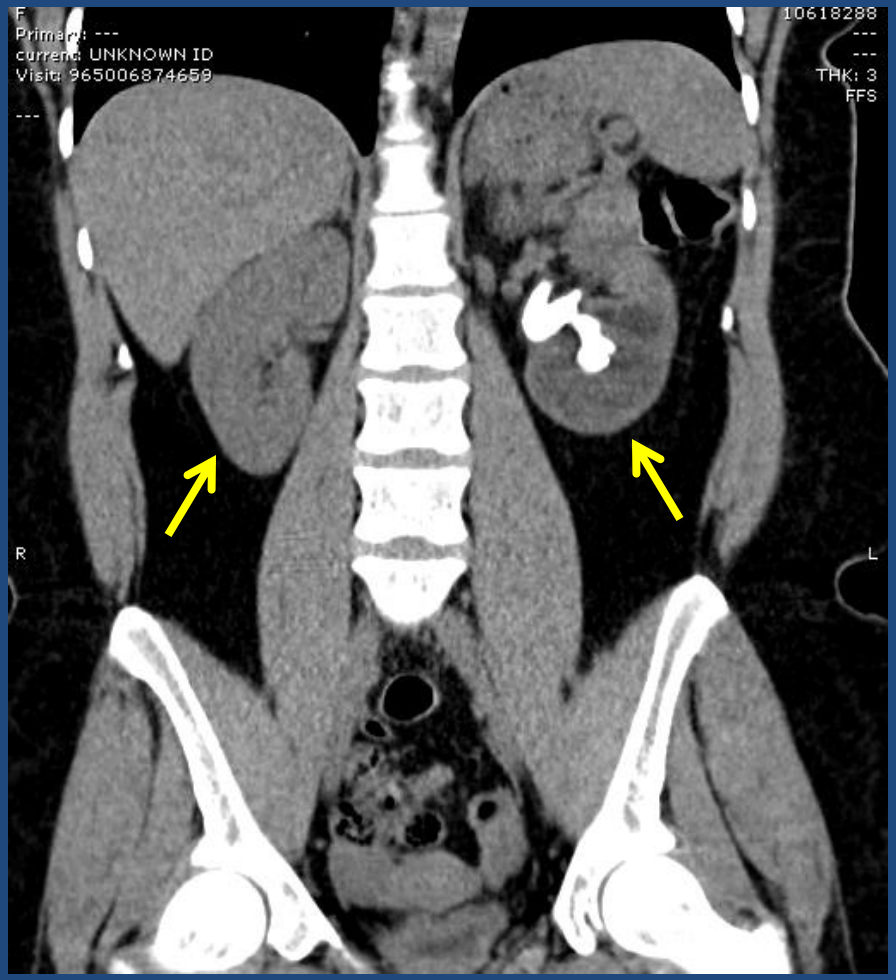

What is the scan plane?

Coronal

Where are the kidneys?

Black area below kidneys?

Retroperitoneal fat

White object in left kidney?

Kidney stone. This large stone, extending out toward the calyces, is called a stag-horn calculus

Do you see hydronephrosis?

What level gray would it be?

Medium (0 Hounsfield #)

There was no evidence of obstruction (no hydronephrosis).

Urine culture: Proteus mirabilis

Management

- You perform percutaneous nephrosto-lithotomy. A flexible telescope is passed through a port placed from the flank into the renal pelvis. If the stone is large (as hers was), a laser is often used to break the stone into small fragments.

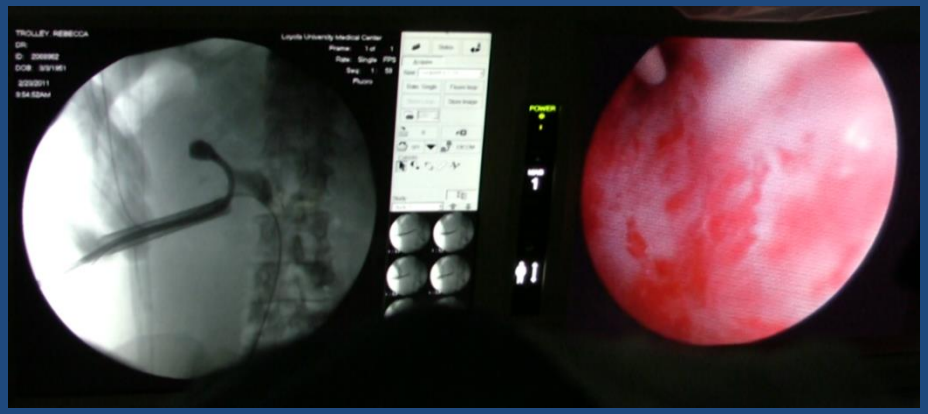

Stone Composition

- Magnesium ammonium phosphate (Struvite) stones form readily in patients who have chronic infection caused by bacteria that produce urease, an enzyme that splits urea into ammonium.
- You were successful in removing all of the stone.
- You control her propensity for urine infections, and this prevents further stone development.
- Ms. Moneybags is so grateful that she funds a research lab in your institution.

Case Review

- Several bacteria produce urease:

  Proteus Enterobacter

  Morganella Serratia

  Klebsiella Providencia

- Urease converts urea to ammonium, raising the pH

- Alkaline urine causes precipitation of magnesium ammonium phosphate (Struvite)

Case History

- 60-year-old Polynesian male had a renal ultrasound as part of an evaluation for proteinuria. He is referred to you after the ultrasound showed a solid mass in the left kidney.
- Past history: coronary artery disease and hypertension
- No family history of malignancies
- 20 pack- year smoker but quit 5 years ago
- A CT scan was obtained to better characterize the mass.
- Lab tests: BUN 21 mg/dl, Creatinine 1.4 mg/dl

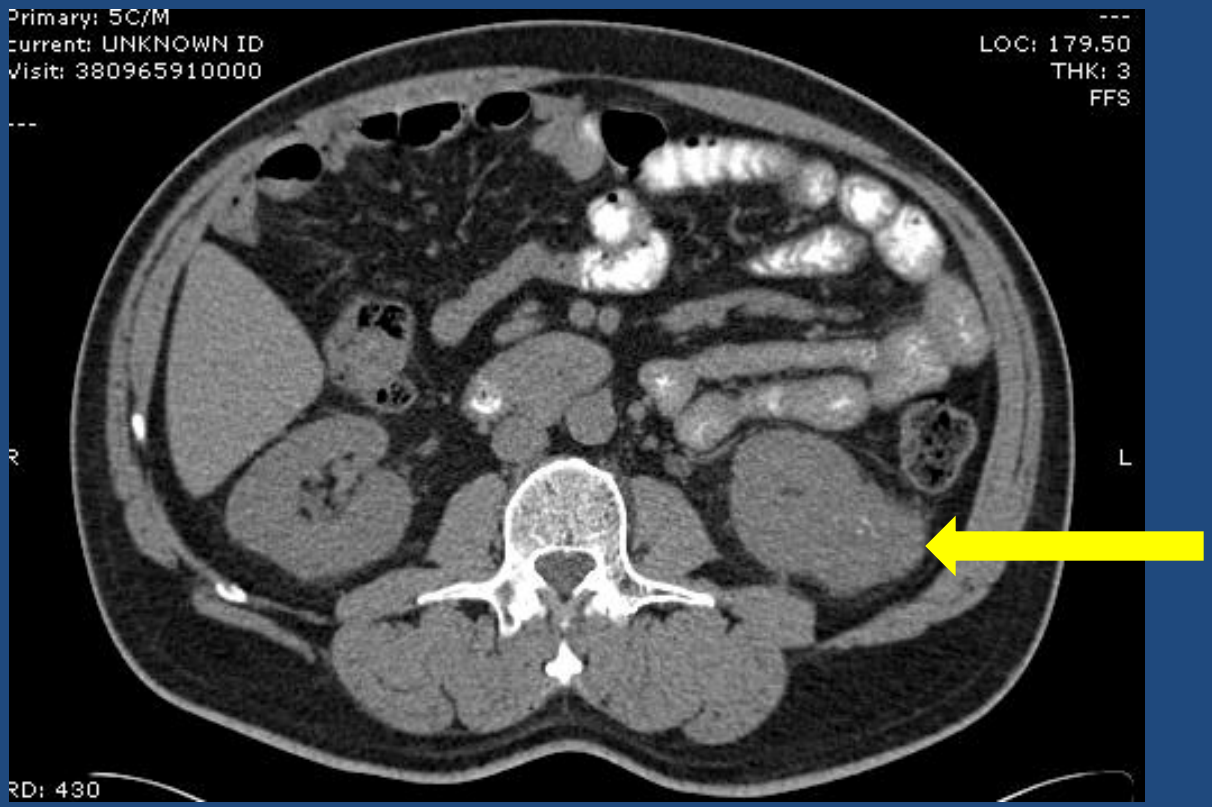

Where is the renal mass?

The lateral border of the left kidney is irregular, but it's difficult to see a distinct mass.

What could we do to differentiate between normal renal tissue and a tumor?

CT Evaluation of Renal Masses

- Oral contrast (gastrografin), helps us to separate the bowel from other structures.
- Intravenous contrast can help to differentiate between normal renal parenchyma and tumors.
- In order to see normal renal parenchyma, the kidney must be well perfused and also have good concentrating ability. Avoid intravenous contrast in patients with renal insufficiency and other conditions that can cause nephropathy.

Risk Factors for Contrast Induced Nephropathy

Serum creatinine > 1.5 mg/dl

Recent contrast exposure

Diabetes

Heart failure

Dehydration

Multiple myeloma

Medications:

- Metformin
- Cyclosporin A
- Cisplatin
- Amphoteracin
- NSAIDs
- Aminoglycosides

Phases of Contrast CT

- The CT image will look different depending on the interval between the contrast infusion and the time images were obtained.
- In general, early phase scans show the arteries and veins and also the cortex.
- Late phase scans show the collecting system.
- Your patient has normal renal function (creatinine = 1.4 mg/dl) and no history of congestive heart failure or diabetes, so you order a CT scan with intravenous contrast.

Early Phase Scan

This image was obtained shortly after intravenous injection of contrast. Note that the aorta is very bright.

The mass in the left kidney concentrates the contrast, although the contrast uptake is irregular unlike the rest of the kidney parenchyma. Most renal tumors show contrast enhancement.

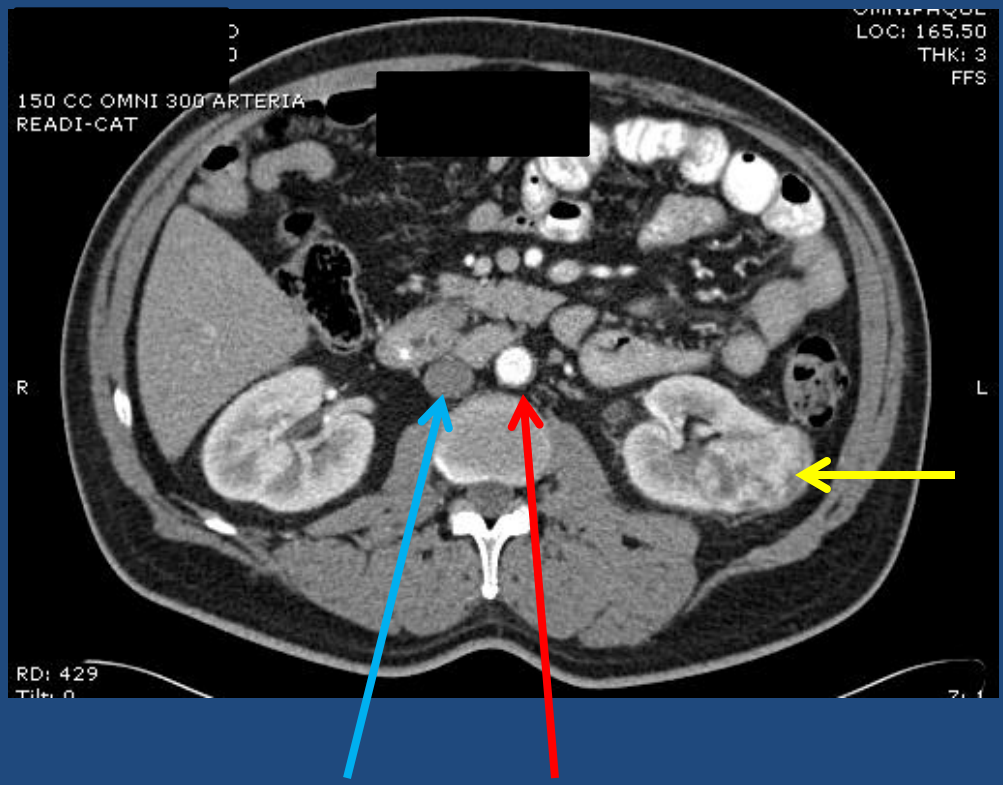

Vena Cava

Aorta

Nephrographic phase

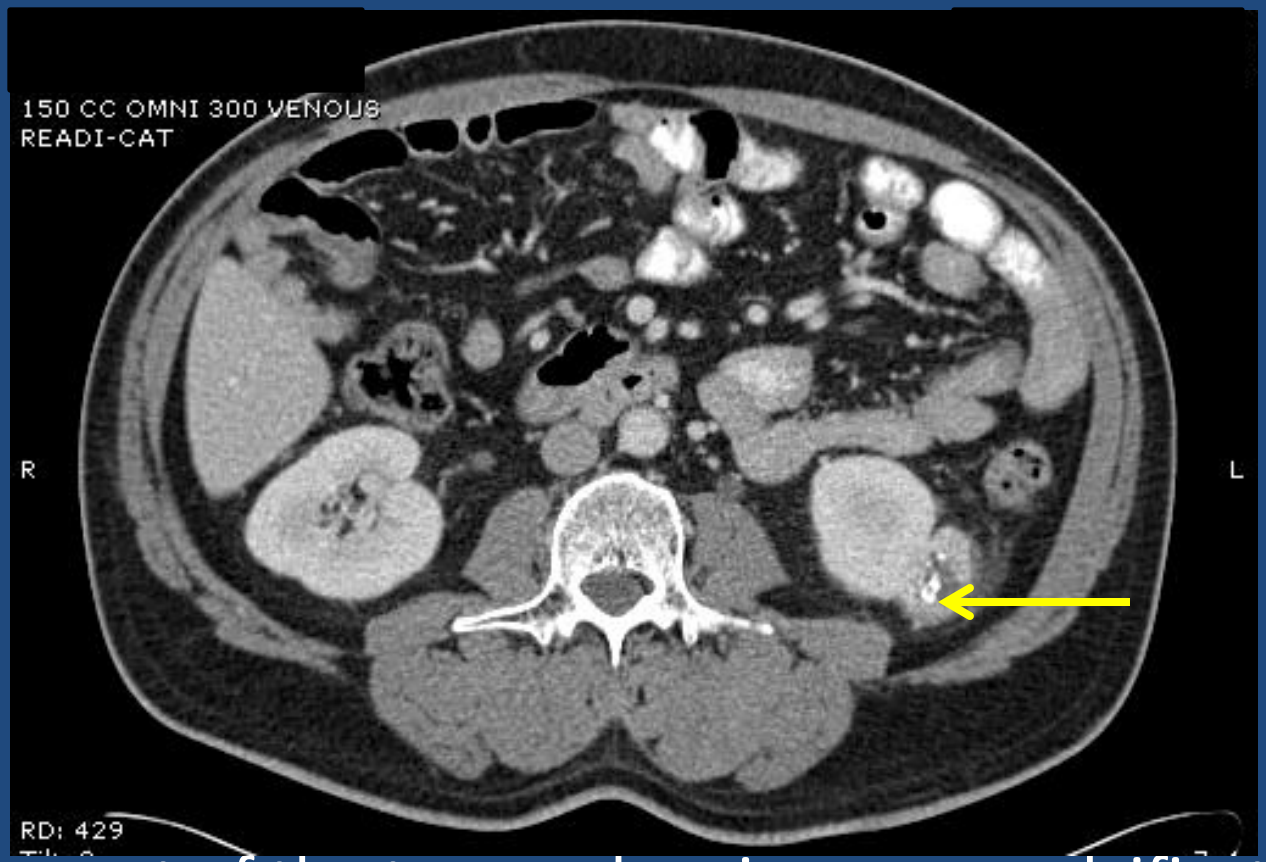

- Another cut of the tumor showing some calcifications in the exophytic portion of the tumor. How did you know that this wasn't contrast in the kidney?
- There is no contrast in the collecting system of either kidney in this early phase scan.

Late (Excretory) Phase

This scan shows contrast in the collecting system. If the tumor arose in the collecting system (transitional cell carcinoma), it would appear as a filling defect in the renal pelvis. This image shows no abnormality of the collecting system; it looks as though the mass is arising from the renal parenchyma. It is most likely a renal cell carcinoma.

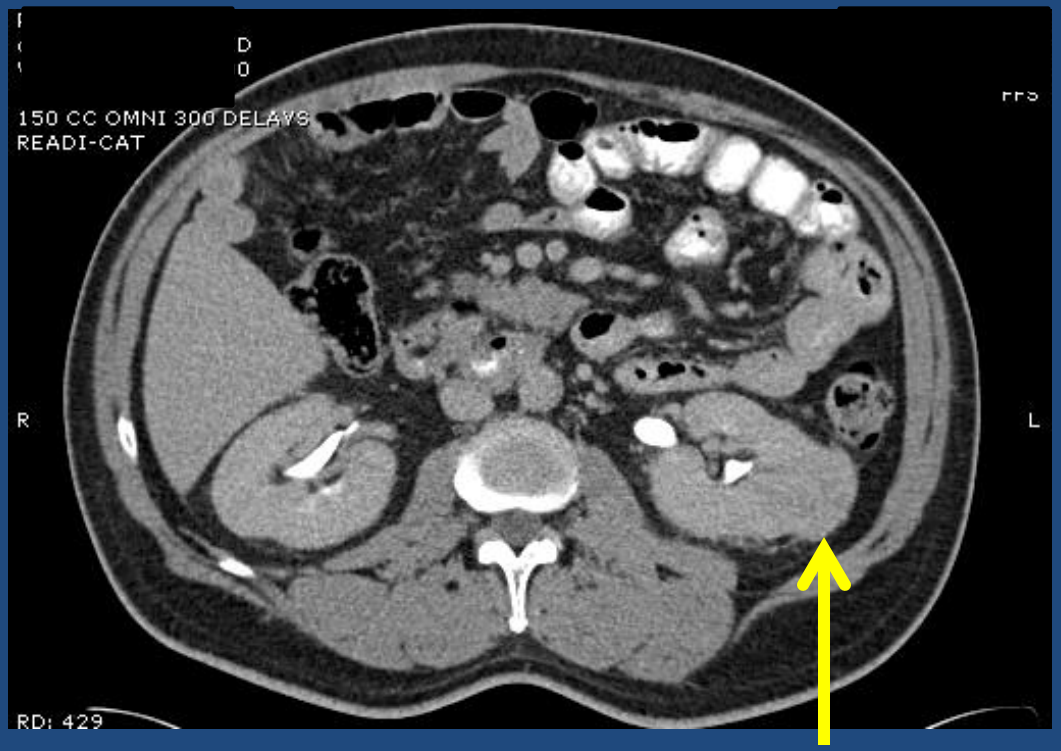

How would your treatment plan differ if the tumor arose from within the renal pelvis or calyx?

Urothelial tumors in the kidney or ureter are most appropriately treated by removal of the kidney and the entire ureter.

Management of Renal Mass

- You found no evidence of metastatic disease. Confident that there was no invasion into the collecting system, you use a surgical robot to perform a partial nephrectomy, leaving healthy renal parenchyma. Frozen sections of the specimen show clear margins and lymph nodes are negative.

- It turns out that your patient is the brother of Tukuaho Tupou IV, the King of Tonga. The family is so grateful that they insist that you spend a month on the Island Nation of Tonga as the King's personal guest.

Case History

- 48-year-old African American female with acute, colicky right flank pain
- Past History: Diabetes (type II), hypertension
- Meds: Lasix, metformin, labetalol

- Exam: obese female, T=39, P=92, BP=155/95
- Tender in right upper quadrant
- U/A: Many WBCs, RBCs, bacteria & 2+ protein
- BUN=42 mg/dl, Creatinine=2.6 mg/dl
- WBC: 18,000 (85% pmn)

Evaluation / Imaging

- Differential diagnosis:
  - Her colicky flank pain suggests a stone.
  - Fever, leukocytosis and urinalysis suggest a urine infection (pyelonephritis).
  - Infection with obstruction is a deadly combination.
- Management
  - Urine culture
  - Antibiotics (broad-spectrum)
- CT scan could identify a stone and hydronephrosis. Would intravenous contrast be helpful to assess her kidney function and possible obstruction?

Intravenous Contrast?

Intravenous contrast might be helpful in demonstrating obstruction, but it is contraindicated in this patient. Why?

Remember the risk factors for contrast nephropathy?

- Serum creatinine > 1.5 mg/dl
- Age > 70y
- Recent contrast exposure
- Diabetes
- Heart failure
- Dehydration
- Multiple myeloma
- Medications:
  - Metformin
  - Cyclosporin A
  - Cisplatin
  - Amphoteracin
  - NSAIDs
  - Aminoglycosides

Intravenous Contrast?

This patient has four of the risk factors for contrast nephropathy?

Serum creatinine > 1.5 mg/dl

Age > 70y Recent contrast exposure

Diabetes Heart failure

Dehydration Multiple myeloma

Medications:

Metformin Cyclosporin A Cisplatin

Amphoteracin NSAIDs Aminoglycosides

You forgo intravenous contrast. Let's look at her CT scan.

The left kidney appears to be normal. Describe the right kidney.

- Enlarged
- Heterogeneous

Some areas are radiolucent.

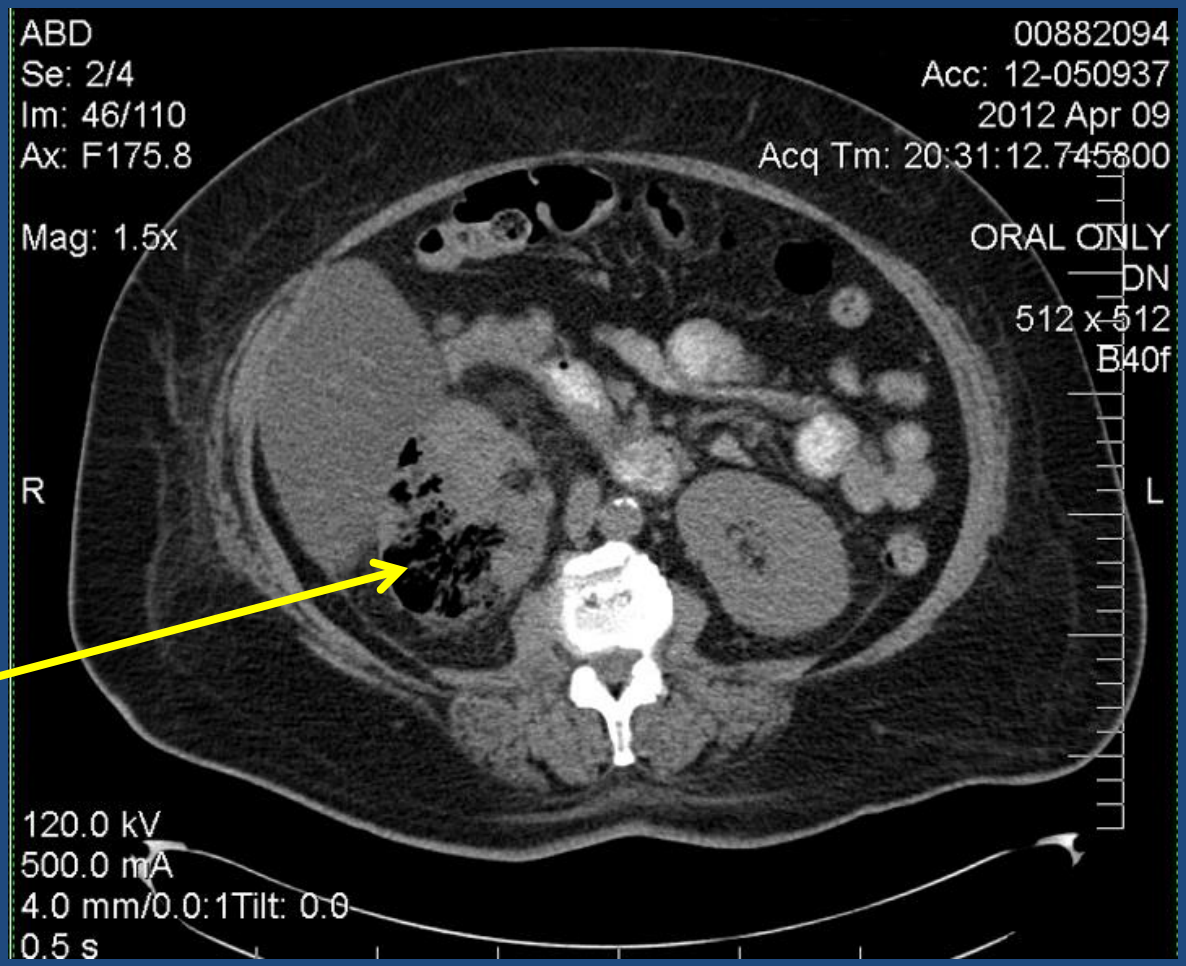

What is this?

Location:

Lateral side of the right kidney

Shape: Irregular

Size: about the same area as the other kidney

Radiodensity?

Radiolucent (very dark)

Notice any other structures with the same radiolucency?

Air in the bowel appears to be of similar radiodensity (low).

What would cause air in the renal parenchyma?

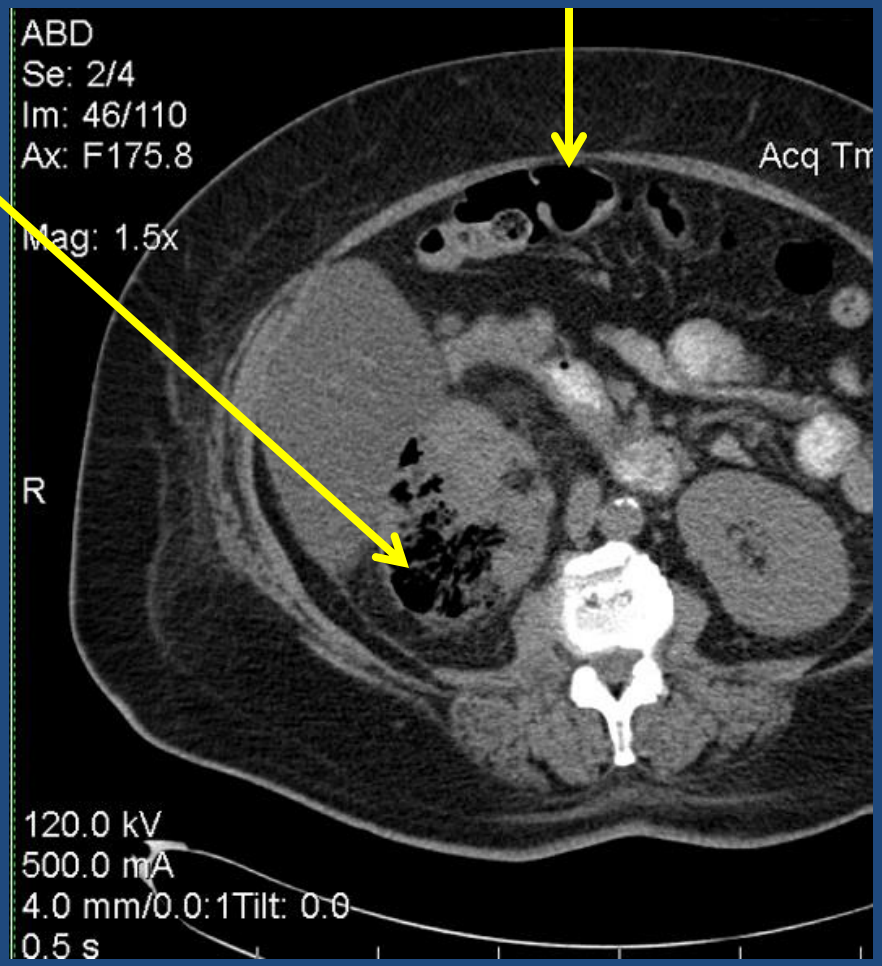

There are two potential causes of air in the kidney:

Infection with a gas producing organism (emphysematous pyelonephritis)

A fistulous tract with the bowel (most commonly from the duodenum to the right renal pelvis).

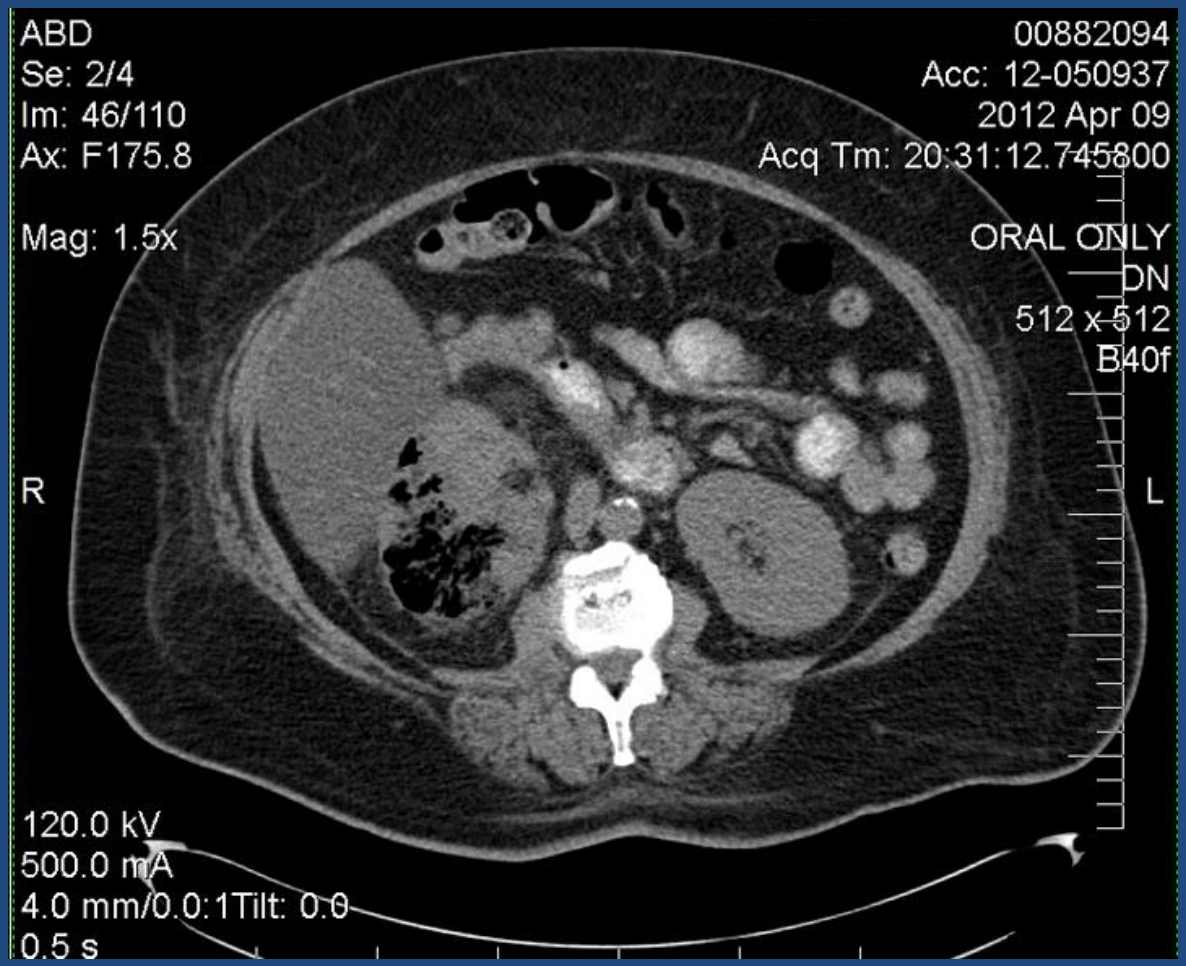

Case Review

Emphysematous pyelonephritis is a potentially fatal condition caused by bacteria that produce gas (e. coli, klebsiella, proteus, pseudomonas , strep and others).

It must be treated promptly with appropriate antibiotics, fluid support and percutaneous drainage if there is obstruction as from a stone.

Nephrectomy is often needed to control the infection.

CT Scan Summary

- CT Scanning gives both anatomic and functional information about the urinary tract.
- Using a reference point (xyphoid), one can determine the location and size of an object
- 3 Orientations give unique perspectives
  - Axial, coronal or sagittal

CT Scan Summary

- Contrast, both i.v. and p.o., can help to differentiate structures in the abdomen.

- Avoid contrast nephropathy in patients with:
  - DM, CHF, multiple myeloma, Age > 70y, dehydration, or recent contrast exposure and nephrotoxic drugs (Metformin, NSAIDs, cyclosporin, cisplatin, aminoglycosides,

CT Scan Summary

- Urine infection caused by bacteria that produce urease can lead to precipitation of magnesium ammonium phosphate (Struvite) kidney stones.

- Emphysematous pyelonephritis is a life threatening infection caused by organisms that produce gas. Prompt treatment includes broad-spectrum antibiotics, cardiovascular support, percutaneous drainage and sometimes nephrectomy.